

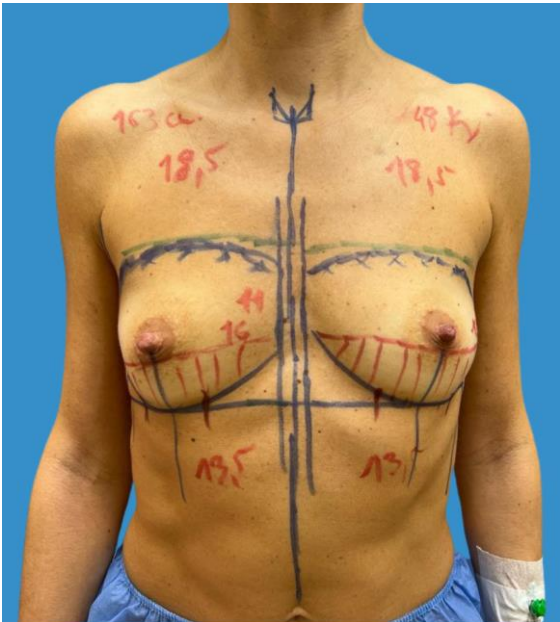
Use of Acellular Pericardial Biological Mesh for Prepectoral and Dual Plane Prosthetic Breast Reconstruction Following Conservative Mastectomies

D. Varvaras¹, F. Frusone¹, A. Sachoulidou², S. Tardioli³, S. D'Onofrio⁴, G. Papadopoulos⁵, T. Al Lawati⁶, V. De Felice¹, L. La Barbera⁷, H. Nina⁸

¹Surgery, Tiberia Hospital, Rome, Italy, ²Second Department of Propaedeutic Surgery, Aristotle University of Thessaloniki, Thessaloniki, Greece, ³Breast Imaging Division - Department of Radiology, Tiberia Hospital, Rome, Italy, ⁴Breast Imaging Division - Department of Radiology, Casa di Cura INI, Grottaferrata, Italy, ⁵Euromedica Geniki Kliniki, Thessaloniki, Greece, ⁶Surgery, Royal Hospital, Muscat, Oman, ⁷Breast Imaging Division - Department of Radiology, San Carlo di Nancy, Rome, Italy, ⁸Surgery, University Medical Center of Tirana Mother Teresa, Tirana, Albania

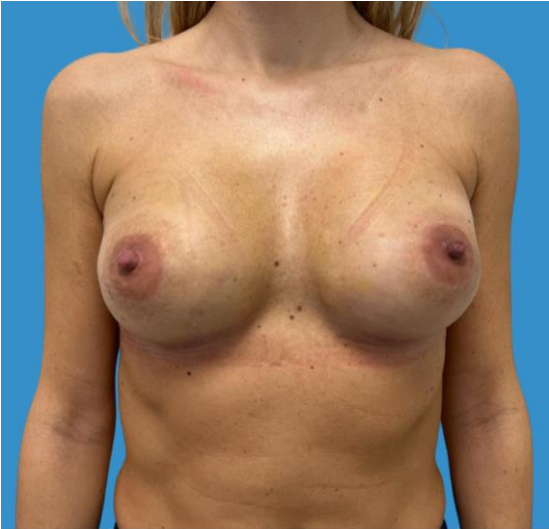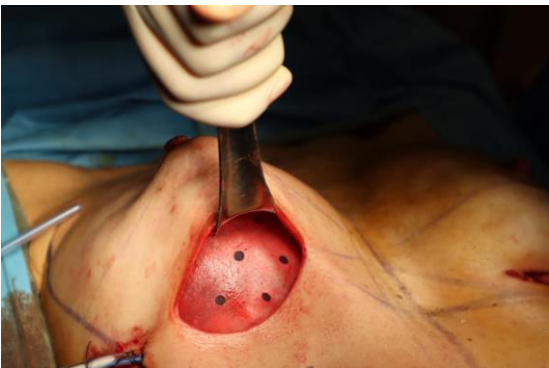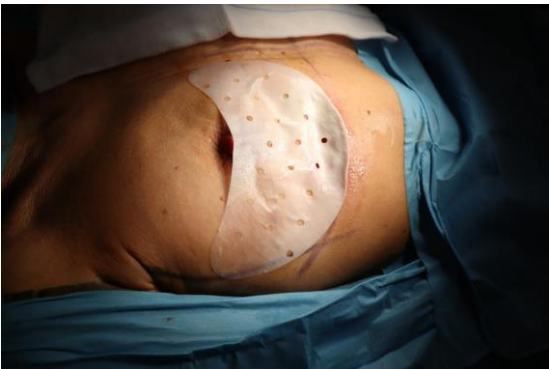Goals

Breast reconstruction plays an important role for quality of life and satisfaction of patients subjected to “conservative” mastectomies (nipple sparing, skin-sparing or skin-reducing), and the research of new surgical techniques, materials and medical devices is currently increasing. In particular, the advent of acellular dermal (ADM) and pericardial (APM) biological meshes has made immediate breast reconstruction possible in more cases, avoiding the use of tissue expanders, improving the quality of reconstruction, and lowering the ratio of critical complications, mainly capsule contracture. On the other hand, the use of APM is still debated, due to some specific side effects related to residual immunogenic biologic material and the productive process itself; for this reason, it is necessary to increase knowledge on tissue inflammation, integration, and remodeling mechanisms. The aim of the study is to assess safety, tolerability, and efficacy of this new APM analyzing ultrasonographic and clinical data.



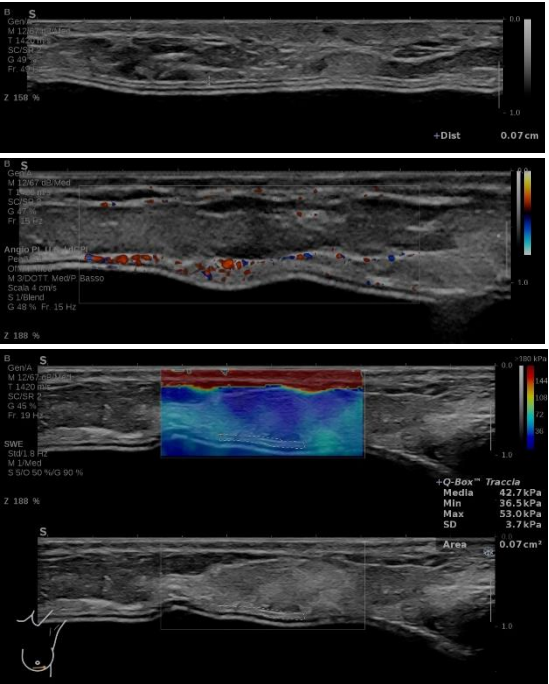
Methods

We performed a prospective observational study using Exashape® for the reconstruction surgery of patients subjected to mastectomy in both dual-plane and prepectoral setting. The primary objective of the study was to evaluate the APM's safety, comparing major and minor complication rates of the two study groups (Exashape® prepectoral, group A, Exashape® dual plane, group B). Secondary objectives were evaluation of tolerability and efficacy



Results

We performed 10 mastectomies followed by reconstruction between 2020 and 2022, for a total of 14 breast implants and 14 APM (9 dual-plane and 5 prepectoral). With a mean follow-up of 13,7 months Finally, in our in vivo ultrasound integration study showed good and predictable integration process in a 12 month period with progressive neovascularization and balancing of viscoelastic properties with superficial tissues, without the development of excessive fibrosis (periprosthetic capsule)



Conclusions

Despite the limited number of patients, our data suggested that breast prosthetic reconstruction with Exashape® APM is a valuable and safe alternative in selected patients, both in the dual plane and the prepectoral settings. Moreover, our clinical and ultrasonographic data could be the base for future studies, leading to a better understanding of biological mesh remodeling and integration process, since the balance of degradation and rebuilding process (inflammation/integration) is the key point in the clinical use of these materials.